

Received: 2020.01.14

Accepted: 2020.05.15

Available online: 2020.06.26

Published: 2020.07.30

Fatal Outcome Consequent to an Endoscopic Full Thickness Resection of a Colonic Lateral Spreading Tumor: A Case Report

Authors' Contribution:

Study Design A
Data Collection B
Statistical Analysis C
Data Interpretation D
Manuscript Preparation E
Literature Search F
Funds Collection G

EF 1 **Giovanni Oliviero**
EF 1 **Mario Gagliardi**
F 2 **Marco Napoli**
EF 3 **Orazio Labianca**
E 4 **Antonio D'Antonio**
EF 3 **Mariano Sica**
ACEF 3 **Attilio Maurano**
ABCDEFG 3 **Claudio Zulli**

1 Gastroenterology Unit, San Giovanni di Dio e Ruggi D'Aragona Hospital, Salerno, Italy
2 Digestive Surgical Endoscopy Unit, Policlinic Agostino Gemelli Foundation, Rome, Italy
3 Digestive Endoscopy Unit, Gaetano Fucito Hospital, Mercato San Severino, Italy
4 Pathological Anatomy Unit, San Giovanni di Dio e Ruggi D'Aragona Hospital, Salerno, Italy

Corresponding Author: Giovanni Oliviero, e-mail: giovanni.olivierounina2@gmail.com
Conflict of interest: None declared

Patient: Male, 77-year-old
Final Diagnosis: Enterocolic fistula
Symptoms: Diarrhea • pain and guarding of the abdomen • weight loss
Medication: —
Clinical Procedure: Colonoscopy with colon biopsy
Specialty: Gastroenterology and Hepatology

Objective: Unusual clinical course

Background: Endoscopic full-thickness resection represents an innovative procedure, used in selected patients that allows lesions en-bloc resection with an integral wall specimen available for histopathological definition. Bleeding and perforation are known to be the most frequent procedure-related adverse events. We report a case of entero-colonic fistula as complication of an endoscopic full-thickness resection.

Case Report: A 77-year-old male, with a personal history of right-hemicolectomy for a colonic adenocarcinoma presented to our department for a routine colonoscopy that showed the presence of a 25 mm lateral spreading tumor localized at about 50 cm from the anal margin. A full-thickness resection of the lateral spreading tumor using the over-the-scope clip device was performed. After 4 weeks, because of abdominal pain, weight loss, diarrhea, and signs of malnutrition, the patient underwent a new colonoscopy showing hyperemic mucosa with ulcerations in all colonic segments and, at the site of the previous endoscopic full-thickness resection, an orifice of an entero-colonic fistula. The histological definition was suggestive for ulcerative proctocolitis and confirmed the presence of small bowel mucosa at fistula orifice. An intussusception at the level of fistula with consequent intestinal obstruction caused a worsening of clinical conditions and finally the patient death for a septic peritonitis.

Conclusions: Full thickness resection represents an innovative tool for en-bloc resection of gastrointestinal tumoral lesion, but procedural complications and limitations must be considered before performing this procedure.

MeSH Keywords: Colonic Neoplasms • Colonic Polyps • Endoscopy, Gastrointestinal • Intestinal Fistula • Postoperative Complications

Abbreviations: NBI – narrow band imaging; FTRD – full-thickness resection device

Full-text PDF: <https://www.amjcaserep.com/abstract/index/idArt/922855>

 1008   3  1  12



Background

Flat colorectal adenomas and early cancers are usually treated using endoscopic mucosal resection and/or endoscopic submucosal dissection. However, these procedures present some limitations (e.g., incomplete en-bloc resection) and high complication rates (e.g., perforation and bleeding) [1,2]. Endoscopic full-thickness resection represents an innovative and effective procedure that can be used in selected patients. Performing closure and cutting of the tissue in one integrated procedure, endoscopic full-thickness resection allows en-bloc resection with an integral wall specimen available for histopathological definition. The main indications for the procedure are: 0–I or 0–II and selected 0–III (Paris classification) [3] colonic lesions with no lifting sign [4], submucosal colonic lesions, recurrent adenomatous lesions previously resected with endoscopic mucosal resection or endoscopic submucosal dissection techniques, and lesions located in difficult anatomic sites, such as diverticulum [5] or appendix where the perforation risk during conventional resection endoscopic techniques is high. Bleeding, perforation, post polypectomy syndrome and also acute appendicitis are known to be the most frequent procedure-related adverse events. To our knowledge, entero-colonic fistula has never been described as a complication of an endoscopic full-thickness resection [6,7].

Case Report

Here we describe a case of a 77-year-old Caucasian male with a personal history of right-hemicolectomy with side-to-side ileum-colon anastomosis for a colonic adenocarcinoma 3 years prior and a family history of colorectal cancer. The histopathology of the resected tumor was “colic adenocarcinoma, moderately differentiated colonic adenocarcinoma (G2) with high grade

dysplasia. The tumor was infiltrating the submucosa with no evidence of carcinomatous lymphangitis. The resection margins were free of tumor and 17 lymph nodes were harvested”.

A routine colonoscopy showed the presence of a 25 mm lateral spreading tumor mixed type (granular and non-granular for the presence of a central depressed area) localized at about 50 cm from the anal margin. Polyp visualization with narrow band imaging (NBI) and magnification showed a pit pattern type IV according to Kudo classification. After 4 weeks, a full-thickness resection of lateral spreading tumor using the over-the-scope clip device (full-thickness resection device, FTRD; Ovesco Endoscopy, Tübingen, Germany) was performed as shown in Figure 1. No immediate or late procedure-related adverse events were registered. The histological definition of the lesion showed a slight submucosal invasion from the muscularis mucosa, sm1 type according to Kikuchi classification (Figure 2). After 4 weeks, patient referred to our center for abdominal pain, weight loss, and diarrhea started 1 week earlier. Routine blood test showed hemoglobin 9 g/dL and signs of malnutrition, and hypoalbuminemia (2.5 g/dL), hyponatremia (125 mEq/L), and hypokalemia (3 mEq/L).

The patient underwent a new colonoscopy showing hyperemic mucosa with superficial and deep ulcerations in all the segments explored. At the site of the previous endoscopic full-thickness resection a large ileocolic fistula was found and remaining colonic mucosa appeared hyperemic with mature erosions and superficial ulcerations as shown in Figure 3 and Video 1. Several biopsies were collected from all segments explored and from the fistula. The histological definition was suggestive for ulcerative proctocolitis and confirmed the presence of small bowel mucosa at the level of fistula orifice. The patient was then hospitalized and began therapy with mesalazine, cortisone, and metronidazole in order to treat the acute phase of proctocolitis.

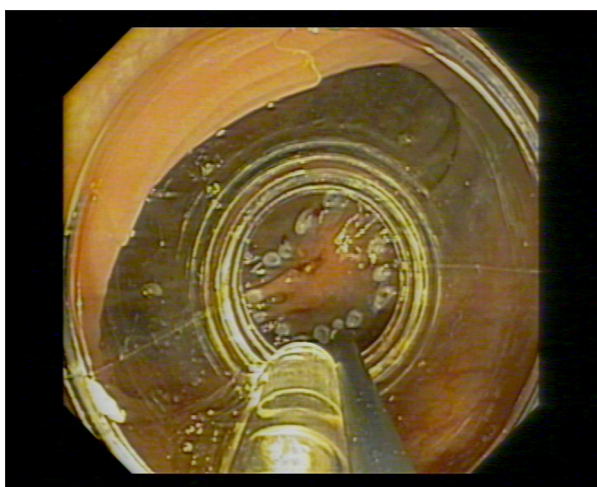


Figure 1. Endoscopic full thickness resection of the lateral spreading tumor using over-the-scope clip device.

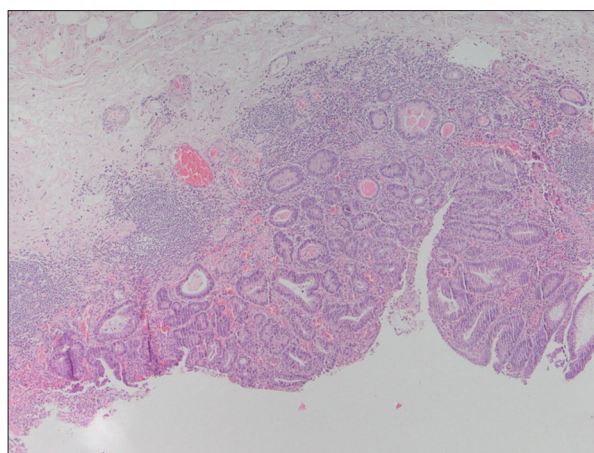


Figure 2. Adenomatous polyp showed an area of intramucosal carcinoma/high-grade dysplasia with involvement of the muscularis mucosae. (hematoxylin and eosin, 4×).

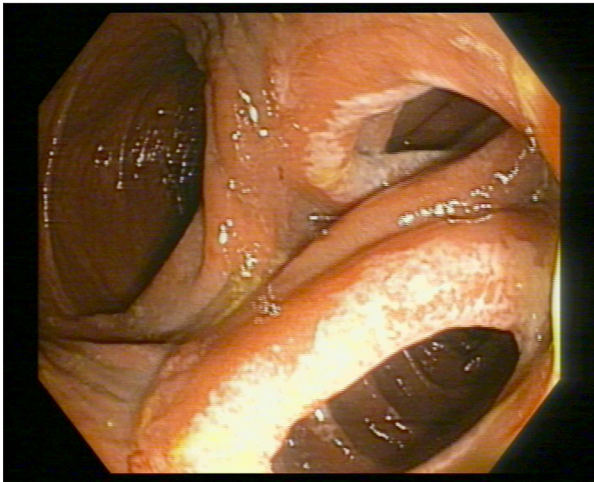


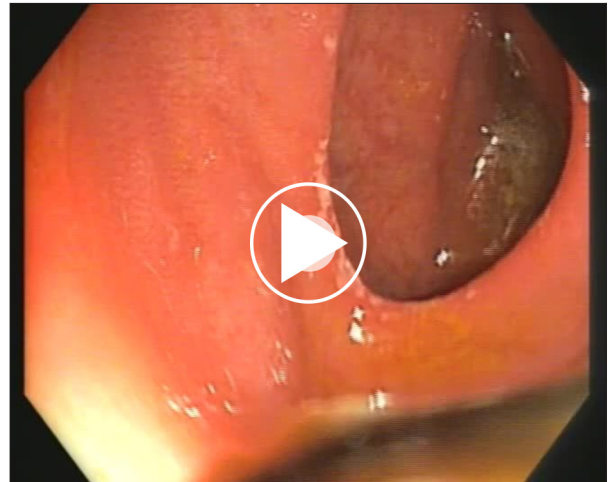Figure 3. The orifice of entero-colonic fistula and remaining hyperemic colonic mucosa with erosions and superficial ulcerations.

A computed tomography of abdomen did not clarify fistula structure and positioning, so a magnetic resonance imaging was performed showing that it was an entero-colic fistula downstream of the Treitz ligament. Given that, the multidisciplinary team, composed by anesthesiologists, surgeons, and gastroenterologists opted to postpone the surgery after optimizing the patient's conditions.

An intussusception at the level of fistula with consequent intestinal obstruction caused a worsening of clinical conditions. An attempt of rescue surgery with the resection of intestinal loops involved was performed. Despite that the patient developed a septic shock and finally died.

Discussion

We discuss the first case of entero-colonic fistula after an endoscopic full-thickness resection procedure. Endoscopic full-thickness resection is an effective and innovative tool to perform en-bloc removal of colonic lesions with non-lifting sign [3,4], submucosal colonic lesions and recurrent adenomatous lesions. The device is composed by an over-the-scope clip able to perform a full thickness resection after forced aspiration or forceps capture of a lesion, previously circumferentially marked using a high-frequency coagulation probe. Endoscopic full-thickness resection allows en-bloc resection with an integral wall specimen available for histopathological definition. Despite that, one of the most important procedure limitations is represented by the impossibility of evaluating the kind and quantity of tissue caught in the cap during forced aspiration or forceps capture. Recently a multicentre prospective study by Schmidt et al. estimated the rates of the most important complications after endoscopic full-thickness



Video 1. The video shows the orifice of entero-colonic fistula with hyperemic mucosa.

resection, specifically bleeding within 1 to 3 days after the procedure (2.2%) and perforation (3.3%) [7]. Similar complication rates were reported in several multicentric studies: Aepli et al. (12.4%); Albrecht et al. (14.9%) [8,9]. Another approach used to perform a full-thickness resection avoiding major complications (e.g., perforation or fistula) is a laparoscopic-endoscopic "rendez-vous". Fukunaga et al., describe this new technique of en-bloc resection of colorectal tumor as performing a full-thickness resection using endoscopy and laparoscopy supportively and concluding the excision with linear staplers. However, this approach minimized the risk of perforation and fistulation, but required a longer hospitalization, a longer operating time and consequently higher cost [10].

Full-thickness resection represents an innovative and effective tool for en-bloc resection of gastrointestinal tumoral lesions, but procedural complications and limitations must be considered before performing this procedure.

Conclusions

Endoscopic full-thickness resection can be considered as an innovative and efficient technique available in difficult cases. To the best of our knowledge, no studies have reported patients with entero-colonic fistula as a complication of endoscopic full-thickness resection of colonic lesions. Future studies are needed to clarify the correct clinical use, applicability, and also possible complications of this technique.

Acknowledgements

We would like to thank all the people who help us to perform the procedure and helped develop this case report, including nurses and auxiliary staff.

Department and Institution where work was done

Digestive Endoscopy Unit of Gaetano Fucito Hospital in Mercato San Severino (SA), Italy.

Conflicts of interest

None.

References:

1. Hori K, Uraoka T, Harada K et al: Predictive factors for technically difficult endoscopic submucosal dissection in the colorectum. *Endoscopy*, 2014; 46: 862–70
2. Schmidt A, Bauerfeind P, Gubler C et al: Endoscopic full-thickness resection in the colorectum with a novel over-the-scope device: first experience. *Endoscopy*, 2015; 47: 719–25
3. The Paris endoscopic classification of superficial neoplastic lesions: esophagus, stomach, and colon: November 30 to December 1, 2002. *Gastrointest Endosc*, 2003; 58(6 Suppl.): S3–43
4. Ishiguro A, Uno Y, Ishiguro Y et al: Correlation of lifting versus non-lifting and microscopic depth of invasion in early colorectal cancer. *Gastrointest Endosc*, 1999; 50(3): 329–33
5. Valli PV, Kaufmann M, Vrugt B, Bauerfeind P: Endoscopic resection of a diverticulum-arisen colonic adenoma using a full-thickness resection device. *Gastroenterology*, 2014; 147(5): 969–71
6. Mão de-Ferro S, Castela J, Dias Pereira A: Endoscopic full-thickness resection of colorectal lesions with the new FTRD system: single-center experience. *GE Port J Gastroenterol*, 2019; 26(4): 235–41
7. Schmidt A, Beyna T, Schumacher B et al: Colonoscopic full-thickness resection using an over-the-scope device: A prospective multicentre study in various indications. *Gut*, 2018; 67(7): 1280–89
8. Aepli P, Criblez D, Baumeler S et al: Endoscopic full thickness resection (EFTR) of colorectal neoplasms with the Full Thickness Resection Device (FTRD): clinical experience from two tertiary referral centers in Switzerland. *United European Gastroenterol J*, 2018; 6(3): 463–70
9. Albrecht H, Raithe M, Braun A et al: Endoscopic full-thickness resection (EFTR) in the lower gastrointestinal tract. *Tech Coloproctol*, 2019; 23(10): 957–63
10. Fukunaga Y, Tamegai Y, Chino A et al: New technique of en bloc resection of colorectal tumor using laparoscopy and endoscopy cooperatively (laparoscopy and endoscopy cooperative surgery - colorectal). *Dis Colon Rectum*, 2014; 57(2): 267–71