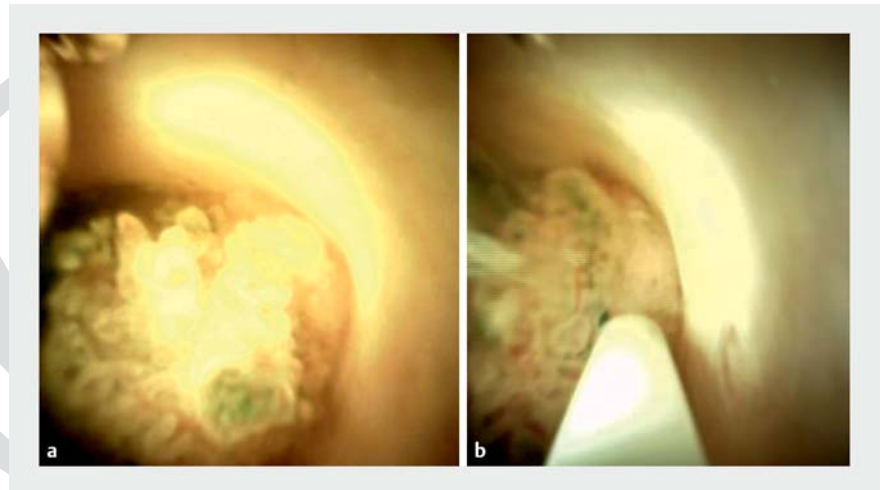


## Use of a cholangioscopy-guided retrieval snare for the macrobiopsy of a choledochal polyp

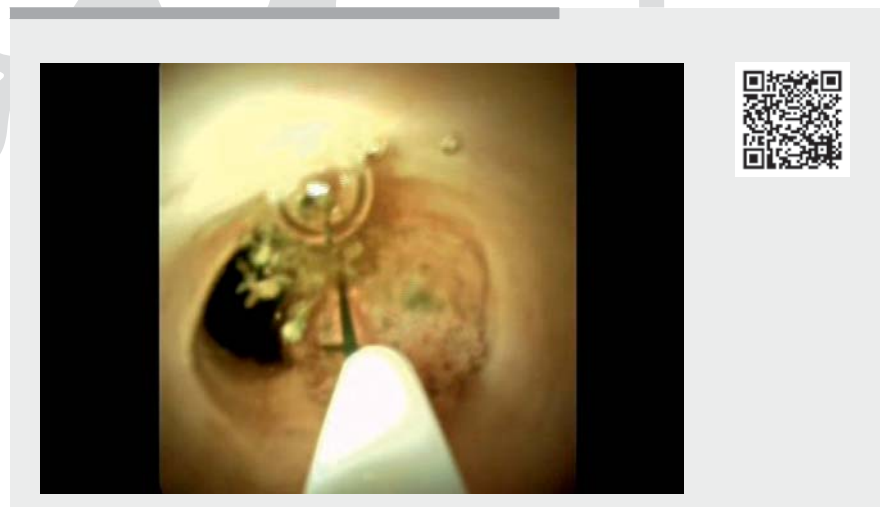A 65-year-old man with a 1-year history of recurrent episodes of right upper quadrant colicky pain presented with this complaint to our outpatient clinic. The patient's past medical history included hypertension. He underwent a transabdominal ultrasound scan, which showed a hypoechoic nodular lesion of 12 mm in the proximal common bile duct (CBD), without evidence of distension of the intrahepatic biliary ducts. Therefore, an endoscopic ultrasound (EUS) was scheduled and performed. The EUS examination confirmed the presence of a hypoechoic nodular lesion of 13×12 mm in the proximal CBD, along with a slight biliary stricture. Given the suspicion of cholangiocarcinoma, endoscopic retrograde cholangiopancreatography (ERCP) was indicated. After informed consent for the procedure and appropriate sedation had been given, ERCP was performed.

Cholangiography showed a slight biliary stricture in the proximal CBD. After sphincterotomy had been performed, we proceeded to peroral intraductal cholangioscopy (IDC) using the Spyglass DS system. IDC showed a polypoid lesion, with a papillary pattern and an irregular undilated vessel (F3-V2) [1], of almost 13 mm in the proximal CBD without hilar involvement (► Fig. 1 a). A cholangioscopy-guided cold macrobiopsy of the choledochal polyp was successfully performed using an IDC snare (Spyglass retrieval snare) and the specimen was collected for histopathological examination (► Fig. 1 b; ► Video 1). At the end of the procedure, the resection site was clear and there was no evidence of either bleeding or biliary leakage.

Histopathological examination showed polypoid fragments with villous architecture and high grade dysplasia, with focal areas of intramucosal adenocarcinoma (► Fig. 2). The patient was therefore referred for surgical evaluation. We, herein, describe a patient with a choledochal polyp who underwent IDC fol-



► Fig. 1 Cholangioscopic images showing: a a polypoid lesion in the common bile duct; b cold macrobiopsy being performed with an intraductal retrieval snare.

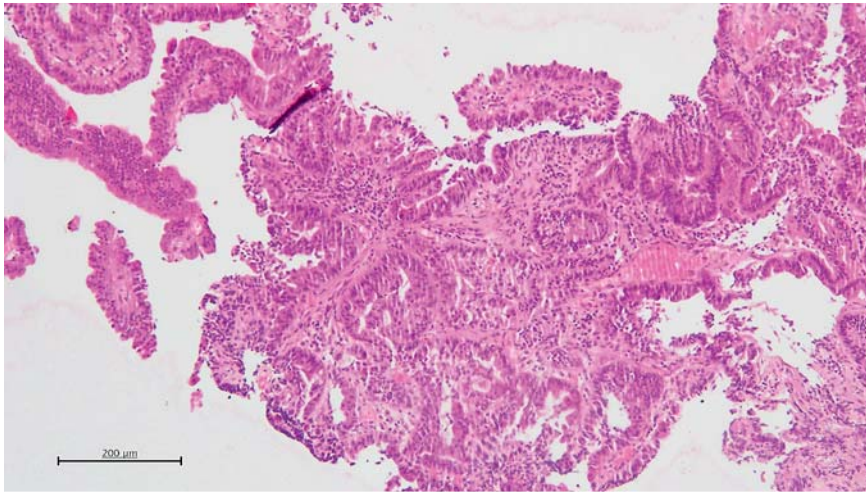


► Video 1 Use of a cholangioscopy-guided retrieval snare for the macrobiopsy of a choledochal polyp.

lowed by macrobiopsy using an IDC retrieval snare. Although the use of an IDC-guided retrieval snare has been previously described for the removal of biliary stones and retained prostheses [2], its use for macrobiopsy of a choledochal polyp has not been previously reported. This case demonstrates the effective use

of an IDC retrieval snare as a valid alternative for the sampling of choledochal lesions to achieve a valid histological diagnosis.

Endoscopy\_UCTN\_Code\_TTT\_1AR\_2AD



► **Fig. 2** Histopathological appearance showing polypoid fragments with villous architecture and high grade dysplasia, with focal areas of intramucosal adenocarcinoma.

## Bibliography

Endoscopy

DOI 10.1055/a-1747-3033

ISSN 0013-726X

published online 2022

© 2022, Thieme. All rights reserved.

Georg Thieme Verlag KG, Rüdigerstraße 14,

70469 Stuttgart, Germany

### ENDOSCOPY E-VIDEOS

<https://eref.thieme.de/e-videos>



*Endoscopy E-Videos* is an open access online section, reporting on interesting cases

and new techniques in gastroenterological endoscopy. All papers include a high quality video and all contributions are freely accessible online. Processing charges apply (currently EUR 375), discounts and waivers acc. to HINARI are available.

This section has its own submission website at

<https://mc.manuscriptcentral.com/e-videos>

## Competing interests

The authors declare that they have no conflict of interest.

## The authors

Claudio Zulli<sup>1</sup>, Mariano Sica<sup>1</sup>, Michele Fusco<sup>1</sup>, Carmela Abbatiello<sup>2</sup>, Antonio D'Antonio<sup>2</sup>, Attilio Maurano<sup>1</sup>, Mario Gagliardi<sup>2</sup>

1 Digestive Endoscopy Unit, Gaetano Fucito Hospital, Mercato San Severino, Salerno, Italy

2 Digestive Endoscopy Unit, San Giovanni di Dio e Ruggi d'Aragona University Hospital, Salerno, Italy

## Corresponding author

**Mario Gagliardi, MD**

Digestive Endoscopy Unit, San Giovanni di Dio e Ruggi d'Aragona University Hospital, Via San Leonardo 84131, Salerno, Italy  
mariogagliardi@outlook.com

## References

- [1] Fukasawa Y, Takano S, Fukasawa M et al. Form-Vessel classification of cholangioscopy findings to diagnose biliary tract carcinoma's superficial spread. *Int J Mol Sci* 2020; 21: 3311
- [2] Fejleh MP, Thaker AM, Kim S et al. Cholangioscopy-guided retrieval basket and snare for the removal of biliary stones and retained prostheses. *VideoGIE* 2019; 4: 232–234